doi: 10.3978/j.issn.2095-6959.2018.12.039
View this article at: http://dx.doi.org/10.3978/j.issn.2095-6959.2018.12.039

伴表皮下浸润性癌的外阴 Paget 病 1 例并文献复习

王晨晨，陈汝蕾，吕京澴

(南京医科大学附属苏州医院，苏州市立医院病理科，江苏 苏州 215002)

[摘　要]　外阴Paget病是一种少见恶性肿瘤，多见于绝经后白人女性，预后较差。本文报道1例74岁绝经后女性，因自觉外阴瘙痒入院，妇检示：左侧大阴唇内侧肿块，约3 cm×2 cm。患者行外阴包块扩大切除术，术后病理诊断为外阴Paget病合并表皮下浸润性癌，临床分期为外阴癌IA期。11个月后，患者左腹股沟淋巴结肿大，术后病理诊断为转移性肿瘤(外阴腺癌)。患者后续未作辅助治疗，随访2.5个月无复发。目前手术是治疗外阴Paget病的首选方法，考虑到术后复发率高，建议密切随访。对于皮下浸润的患者，应考虑化疗或局部放疗。

[关键词]　外阴Paget病；浸润性癌；治疗；预后

Vulvar Paget's disease with subcutaneous invasive carcinoma: A case report and literature review

WANG Chenchen, CHEN Rulei, LÜ Jinghuan

(Department of Pathology, The Affiliated Suzhou Hospital of Nanjing Medical University, Suzhou Municipal Hospital, Suzhou Jiangsu 215002, China)

Abstract　Primary cutaneous Paget's disease is a rare malignant tumor that occurs in postmenopausal white women and has a poor prognosis. A 74-year-old postmenopausal woman was admitted to the hospital with pruritus vulvae. The gynecological examination showed that the medial mass of the left labia majora with 3 cm × 2 cm. The patient underwent extended excision of vulva masses. Postoperative pathological diagnosis was vulvar Paget's disease with subcutaneous invasive carcinoma. The clinical stage was IA stage of vulvar carcinoma. Eleven months later, the patient had enlarged left inguinal lymph nodes and was pathologically diagnosed as a metastatic tumor (vulvar adenocarcinoma). Patients were followed up for 2.5 months without adjuvant therapy. Currently, surgery is the first choice for vulvar Paget's disease. Considering the high recurrence rate, close follow-up is recommended. For patients with subcutaneous infiltration, chemotherapy or local radiotherapy should be considered.

Keywords　vulvar Paget's disease; invasive carcinoma; treatment; prognosis

外阴Paget病是一种罕见的疾病，其发生率不到外阴恶性肿瘤的1%[1-2]，因其早期临床症状不具特异性，而常易误诊。1901年Dubreuilh首次报道1例外阴病变，发现其组织病理学形态与之前James Paget描述的发生在乳头和乳晕上的湿疹样病变相同[3]。该病变位于表皮，可累及皮肤附属器，伴间

收稿日期 (Date of reception)：2018–09–10
通信作者 (Corresponding author)：吕京澴，Email: 27970561@qq.com

质内浸润的病变占外阴Paget病的15%~20%[4]。国外多为个案报道，而国内鲜有报道，临床上对于伴间质浸润的外阴Paget病病理学特性及联合治疗方式等尚不明确。本文现报道1例伴表皮下浸润性癌、并出现淋巴结转移的外阴Paget病，旨在探究其组织病理学特征、组织起源、治疗及预后。

1 临床资料

患者女，74岁(孕3，产3)，因外阴瘙痒2个月余在当地医院就诊，妇检示：左侧大阴唇内侧肿块，直径约1 cm。活检病理诊断：送检组织表面被覆鳞状上皮，皮下见巢状小圆细胞，部分细胞质透亮，血管扩张。予口服抗生素治疗，自述肿块减小，停药后反复。随诊期间，外阴肿块逐渐增大，遂收治入南京医科大学附属苏州医院，妇检示：外阴红肿，左侧大阴唇见3 cm×2 cm大的肿块，质硬，表面破溃，有轻压痛，无波动感，阴道畅，宫颈炎。患者于腰麻下择期行外阴包块扩大切除术，术中冰冻示：Paget病合并表皮下浸润性癌。手术标本肉眼观示：皮肤组织1块，大小3 cm×2.5 cm×1.3 cm，表面见一结节状隆起，大小1.4 cm×1cm，高出皮肤0.7 cm，切面淡黄色。常规组织病理学诊断为外阴Paget病合并表皮下浸润性癌，紧靠一侧切缘。镜下观察表皮基底层中肿瘤细胞以腺体样结构多见，中表层则呈小簇样及单个分布，瘤细胞核大，深染异型，可见核仁，细胞质丰富透明或嗜酸性(图1)。真皮层内肿瘤细胞呈巢状，大片状密集排列，表现为显著的浸润性生长方式，附属器消失殆尽，瘤巢中可见丰富树枝状的血管网。浸润灶中肿瘤细胞形态与表皮内基本一致，且核分裂易见(图2)。免疫组织化学结果示：肿瘤细胞ER(90%强阳性)，CK7，CK18，CEA均阳性，Ki-67(20%阳性)，CK5/6，PR，P53，P63，S-100，HMB45阴性(图3)。临床最终诊断为外阴癌IA期。

术后11个月，患者无明显诱因下发现左侧腹股沟处肿块，无疼痛感，外院B超示：左侧腹股沟区见数个低回声区，边界清，其一大小23 mm×17 mm，彩色多普勒超声(color Doppler flow imaging，CDFI)点状血流信号。至南京医科大学附属苏州医院进一步体格检查示：左腹股沟处触及2.5 cm肿块，质硬、光滑、活动度差，表面皮肤无破溃。左侧外阴皮肤增厚、潮红，淡黄色分泌物黏附，大阴唇术后样改变。患者于腰麻下行左腹股沟淋巴结切除术。手术标本肉眼检查示：淋巴结1枚，大小2.5 cm×2 cm×1.5 cm，局灶已切开，切面灰黄色。镜下观察淋巴结正常滤泡结构消失，取代以大片状分布的肿瘤细胞，间质可见分支状的血管，瘤细胞胞质丰富，透亮或嗜伊红色，核居中，核仁较明显，核分裂易见(图4)。免疫组织化学结果示：肿瘤细胞CK7，EMA，CEA，CK高阳性，Ki-67(15%阳性)，CD45，CK5/6，CK20，S-100，HMB45，Malen-A，GCDFP-15阴性(图5)。结合免疫组织化学诊断为转移性肿瘤(外阴腺癌)。

临床考虑患者年龄较大，且结合患者自身意愿，未作后续辅助治疗，随访2.5个月无复发。

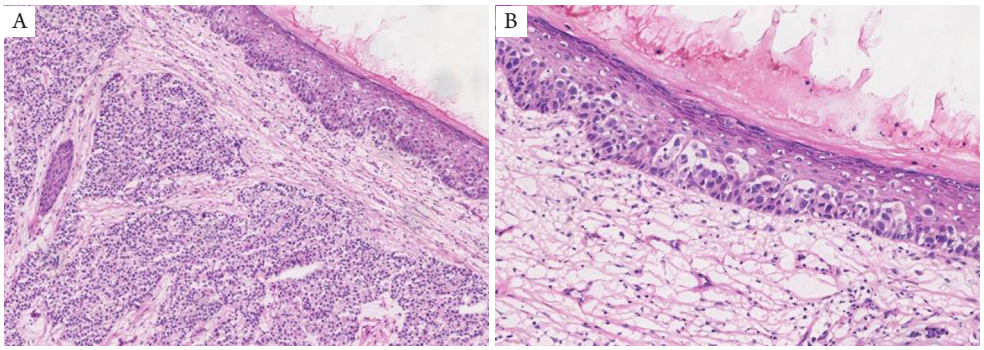

图1 外阴Paget病表皮内Paget细胞特点

Figure 1 Characteristics of Paget cells in epidermis of vulvar Paget's disease

(A)表皮内Paget细胞呈巢状、小簇样、单个浸润等结构生长(HE，×100)；(B)Paget细胞核大，深染异型，可见核仁，细胞质丰富透明或嗜酸性(HE，×200)。

(A) Paget cells in epidermis grew as nests, small clusters, single infiltration and other structures (HE, ×100); (B) Paget cells had large nuclei, hyperchromatic heteromorphism, nucleolus, cytoplasm rich transparent or eosinophilic (HE, ×200).

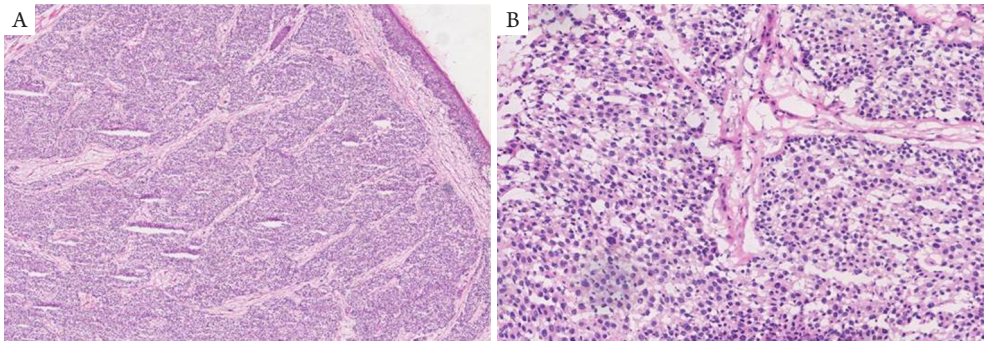

图2 外阴Paget病表皮下浸润灶特点

Figure 2 Characteristics of subcutaneous infiltration in vulvar Paget's disease

(A)真皮层内Paget细胞呈巢状，大片状排列，瘤中可见丰富树枝状的血管网(HE，×40)；(B)浸润灶中瘤细胞形态与表皮内基本一致(HE，×200)。

(A) Paget cells in the dermis were nested and arranged in large sheets, and abundant dendritic vascular net could be seen in the tumor nest (HE, ×40); (B) The morphology of tumor cells in the infiltrating lesions was basically the same as that in the epidermis (HE, ×200).

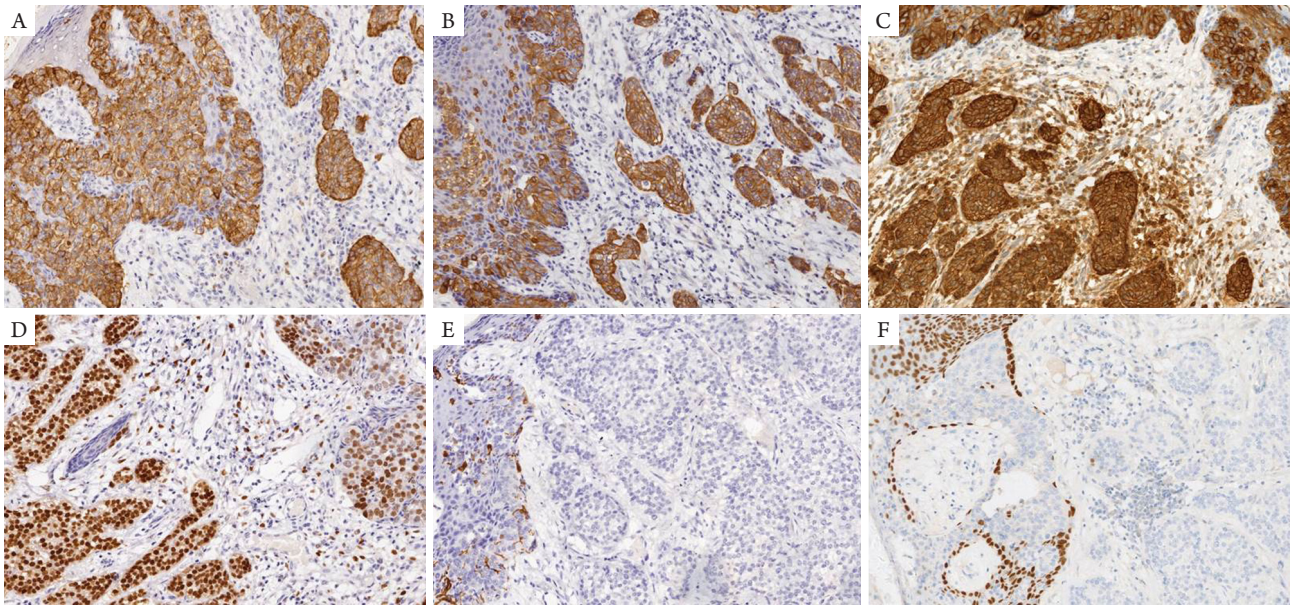

图3 外阴Paget病及皮下浸润灶免疫组织化学染色

Figure 3 Immunohistochemical staining of vulvar Paget's disease and subcutaneous infiltrates

(A)CK7表皮内及浸润灶中Paget细胞阳性，正常表面鳞状上皮阴性(×200)；(B)CK18表皮内及浸润灶中Paget细胞阳性，正常表面鳞状上皮阴性(×200)；(C)CEA表皮内及浸润灶中Paget细胞阳性，正常表面鳞状上皮阴性(×200)；(D)ER表皮内及浸润灶中Paget细胞90%阳性(×200)；(E)HMB45表皮内及浸润灶中Paget细胞阴性，正常表面鳞状上皮散在色素阳性(×200)；(F)P63表皮内及浸润灶中Paget细胞阴性，正常表面鳞状上皮阳性(×200)。

(A) Paget cells in epidermis and infiltrating foci were CK7 positive, while normal surface squamous epithelium was negative (×200); (B) Paget cells in epidermis and infiltrating foci were CK18 positive, while normal surface squamous epithelium was negative (×200); (C) Paget cells in epidermis and infiltrating foci were CEA positive, while normal surface squamous epithelium was negative (×200); (D) Paget cells in epidermis and infiltrating foci were ER 90% positive (×200); (E) Paget cells in epidermis and infiltrating foci were HMB45 negative (×200); (F) Paget cells in epidermis and infiltrating foci were P63 negative, while normal surface squamous epithelium was positive (×200).

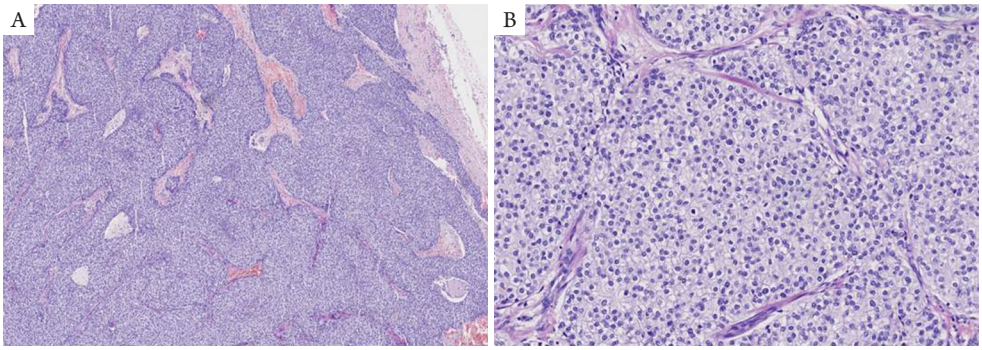

图4 左腹股沟肿大淋巴结特点

Figure 4 Characteristics of left inguinal lymph nodes

(A)淋巴结滤泡结构消失，可见大片状分布的肿瘤细胞，间质可见分支状的血管(HE，×40)；(B)瘤细胞胞质丰富，透亮或者嗜伊红色，核居中，核仁较明显(HE，×200)。

(A) The follicular structure of the lymph nodes disappeared, with large patches of tumor cells and branched blood vessels in the stroma (HE, ×40); (B) Tumor cells are abundant in cytoplasm, bright or eosin, and nucleolus in the middle (HE, ×200).

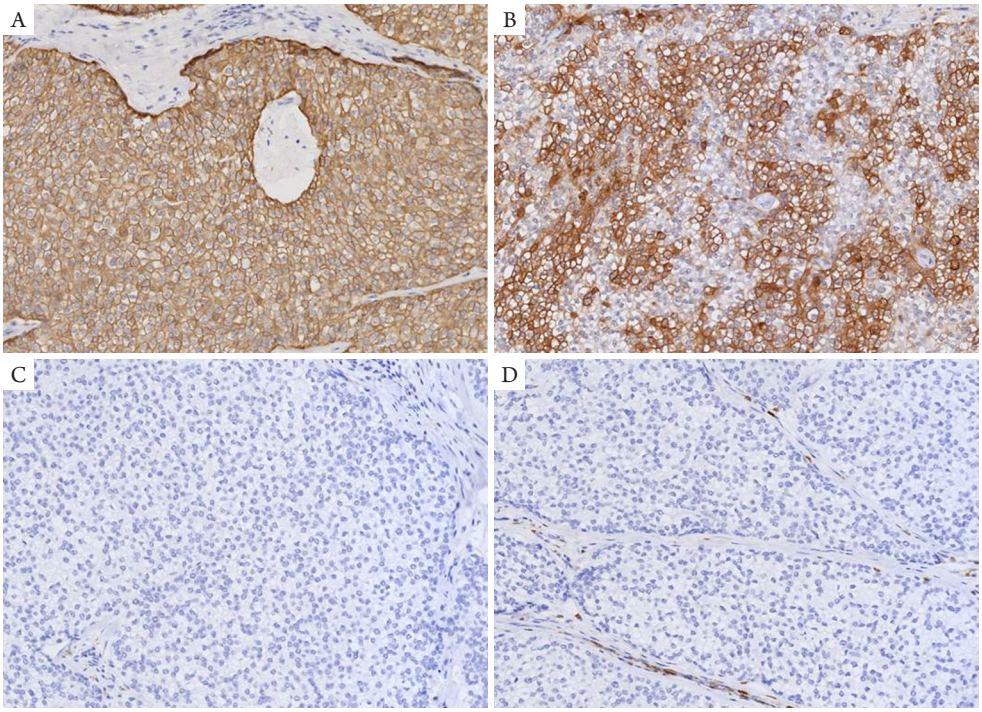

图5 左腹股沟肿大淋巴结免疫组织化学染色(×200)

Figure 5 Immunohistochemical staining of left inguinal lymph nodes (×200)

(A)CK7阳性；(B)CEA阳性；(C)HMB45阴性；(D)CD45阴性。

(A) CK7 positive expression; (B) CEA positive expression; (C) HMB45 negative expression; (D) CD45 negative expression.

2 讨论

乳腺外Paget病为少见的恶性肿瘤，发病年龄为50~80岁老年女性，男性可见，好发部位为外生殖器、肛周、脐周、腋窝[5]。外阴Paget病是乳腺外Paget病最常见部位，是一种罕见的上皮内腺癌[6]，好发于绝经后白人女性，发病年龄为60~70岁[7-8]。临床早期表现为瘙痒、疼痛，湿疹样改变，表皮色素失禁，中后期逐渐进展成溃疡、结节样肿块[9]。文献[10]报道以上的症状可以持续30年之久，且由于临床表现无特征性而易被误诊，需要与以下疾病相鉴别：皮肤念珠菌病、股癣、

脂溢性皮炎、银屑病、Bowen病或黑色素瘤等[11]。乳腺外Paget病分为原发性与继发性。原发性起源于皮肤，Hashemi等[12]曾报道乳腺外Paget病可能起源于托克细胞，它是上皮透明细胞，位于乳晕和乳头区域、外阴部和其他顶泌腺区域，托克细胞增生可能是原发乳房外Paget病的前兆；继发性仅占5%，主要起源于泌尿生殖系统和下消化道肿瘤，侵犯外阴皮肤，其组织学特征与原发性相似，但免疫组织化学特点有所不同[10]。

乳腺外Paget病的镜下特征为典型Paget细胞呈单个或小簇状分布于表皮内，呈小巢团状或腺体样生长于基底部。瘤细胞大而圆，核大深染，核仁明显，胞质空泡状，部分可嗜酸性。在乳腺外Paget病中，瘤细胞的多样性生长特征可能预示浸润性进展[13]。本文病例正是具有了上述多样性生长方式，且表皮下浸润灶中的瘤细胞呈巢片状生长，其形态与表皮中瘤细胞相似。浸润性Paget病浸润深度>1 mm时，易出现脉管侵犯，局部淋巴结转移及复发，提示预后不佳[14]。本病例伴表皮下大片浸润灶，11个月后遂发生淋巴结转移印证了这一观点。Fukuda等[15]研究发现浸润性Paget病的转移机制主要是通过激活RAS-RAF-MEK-ERK，PI3K-Akt-mTOR或雄激素-AR信号通路。Paget细胞还可与其他细胞的相互作用，如瘤灶中的内皮细胞和$CD163^+ARG1^+$巨噬细胞，通过CXCR4-SDF-1和RANKL-RANK信号通路建立良好的肿瘤微环境，从而促进Paget细胞的转移。

外阴Paget病需与以下疾病相鉴别：1)继发性外阴Paget病，来源于泌尿生殖系统及下消化道肿瘤，原发性外阴Paget病示CK7，CEA阳性[16-17]，而CK20，CDX2等阴性，继发性病变则相反。本病例临床已排除泌尿系统和消化道肿瘤。2)Paget样原位鳞癌，该病变CK5/6，P63，CK高呈阳性，原发性外阴Paget病则阴性。3)黑色素瘤，该病变S-100，HMB45，Malen-A呈阳性，原发性外阴Paget病则阴性。此外，临床应加强女性两癌筛查、结肠镜检查、尿检、前列腺特异性抗原检测等检查方式[18]，做到早诊断、早治疗。

目前对外阴Paget病主要治疗手段为手术扩大切除，但术后40%~45%病例复发[19]。Bae等[20]研究表明：用Mohs显微外科(MMS)治疗乳腺外Paget病，相比广泛局部切除术，其复发率显著降低。由于Paget细胞常呈跳跃性及灶性生长，即使手术切缘阴性，也不能保证无瘤细胞残存。本病例手术切缘阴性，依然出现淋巴结转移，因此即使切缘阴性也应密切随访。其他治疗方式包括激光治疗、放射治疗、局部治疗或甚至化学治疗，单独放射治疗是治疗病变广泛不能手术者或有药物禁忌证者的替代方法。存在与局部复发相关的危险因素时，如淋巴结转移、手术切缘接近阳性或阳性、发生于会阴、肿瘤直径大者、多灶性病变等，此时可考虑辅助放射治疗[21]。对于手术后切缘阳性者，使用5%咪喹莫特乳膏涂抹病灶，文献[22]报道约70%病例完全缓解，16%病例部分缓解。对于术后淋巴结转移患者，可行化学治疗如小剂量5-FU/顺铂(FP)、FECOM(5-FU、表阿霉素、卡铂、长春新碱，以及丝裂霉素C)，多西紫杉醇单药、S-1单药、多西他赛和S-1联合治疗等[15]。影响预后的因素包括：Paget病浸润深度，病变范围，淋巴结转移情况，以及潜在其他并发肿瘤等[16]。

参考文献

1. Lam C, Funaro D. Extramammary Paget's disease: summary of current knowledge[J]. Dermatol Clin, 2010, 28(4): 807-826.
2. Delport ES. Extramammary Paget's disease of the vulva: an annotated review of the current literature[J]. Australas J Dermatol, 2013, 54(1): 9-21.
3. Stapleton JJ. Extramammary Paget's disease of the vulva in a young, black woman. A case report with histogenic confirmation by immunostaining[J]. J Reprod Med, 1984, 29(7): 444-446.
4. Herrel LA, Weiss AD, Goodman M, et al. Extramammary Paget's disease in males: survival outcomes in 495 patients[J]. Ann Surg Oncol, 2015, 22(5): 1625-1630.
5. Shepheld V, Davidson EJ, Davies-Humphreys J. Extramammary Paget's disease[J]. BJOG, 2005,112(3): 273-279.
6. Shaco-Levy R, Bean SM, Vollmer RT, et al. Paget disease of the vulva: a study of 56 cases[J]. Eur J Obstet Gynecol Reprod Biol, 2010, 149(1): 86-91.
7. Kanitakis J. Mammary and extramammary Paget's disease[J]. J Eur Acad Dermatol Venereol, 2007, 21(5): 581-590.
8. Tanaka VD, Sanches JA, Torezan L, et al. Mammary and extramammary Paget's disease: a study of 14 cases and the associated therapeutic difficulties[J]. Clinics (Sao Paulo), 2009, 64(6): 599-606.
9. Parashurama R1, Nama V, Hutson R. Paget's disease of the vulva a review of 20 years' experience[J]. Int J Gynecol Cancer, 2017, 27(4): 791-793.
10. Jones IS, Crandon A, Sanday K. Paget's disease of the vulva: diagnosis and follow-up key to management; a retrospective study of 50 cases from Queensland[J]. Gynecol Oncol, 2011, 122(1): 42-44.

11. Laxmisha C, Thappa DM, Jaisankar TJ. Primary vulvar Paget disease the importance of clinical suspicion[J]. Dermatol Online J, 2003, 9(5): 1.
12. Hashemi P, Kao GF, Konia T, et al. Multicentric primary extramammary paget disease: a Toker cell disorder?[J]. Cutis, 2014, 94(1): 35-38.
13. Shiomi T, Yoshida Y, Shomori K, et al. Extramammary Paget's disease: evaluation of the histopathological patterns of Paget cell proliferation in the epidermis[J]. J Dernlatol, 2011, 38(11): 1054-1057.
14. Yamada Y, Matsumoto T, Arakawa A, et al. Evaluation using a combination of lymphatic invasion on D2-40 immunostain and depth of dermal invasion is a strong predictor for nodal metastasis in extramammary Paget's disease[J]. Pathol Int, 2008, 58(2): 114-117.
15. Fukuda K, Funakoshi T. Metastatic extramammary Paget's disease: pathogenesis and novel therapeutic approach[J]. Front Oncol, 2018, 8: 38.
16. Lloyd J, Flanagan AM. Mammary and extramammary Paget's disease[J]. J Clin Pathol, 2000, 53(10): 742-749.
17. Wang EC, Kwah YC, Tan WP, et al. Extramammary Paget's disease: Immunohistochemistry is critical to distinguish potential mimickers[J]. Dermatol Online J, 2012, 18(9): 4.
18. van der Linden M, Meeuwis KA, Bulten J, et al. Paget disease of the vulva[J]. Crit Rev Oncol Hematol, 2016, 101: 60-74.
19. Barmon D, Kataki AC, Imchen L, et al. Extra mammary Paget's disease of the vulva[J]. J Midlife Health, 2012, 3(2): 100-102.
20. Bae JM, Choi YY, Kim H, et al. Mohs micrographic surgery for extramammary Paget disease: A pooled analysis of individual patient data[J]. J Am Acad Dermatol, 2013, 68(4): 632-637.
21. Tolia M, Tsoukalas N, Sofoudis C, et al. Primary extramammary invasive Paget's vulvar disease: what is the standard, what are the challenges and what is the future for radiotherapy?[J]. BMC Cancer, 2016, 16: 563.
22. Dogan A, Hilal Z, Krentel H, et al. Paget's disease of the vulva treated with imiquimod: case report and systematic review of the literature[J]. Gynecol Obstet Invest, 2017, 82(1): 1-7.

本文引用：王晨晨, 陈汝蕾, 吕京澴. 伴表皮下浸润性癌的外阴Paget病1例并文献复习[J]. 临床与病理杂志, 2018, 38(12): 2743-2748. doi: 10.3978/j.issn.2095-6959.2018.12.039

Cite this article as: WANG Chenchen, CHEN Rulei, LÜ Jinghuan. Vulvar Paget's disease with subcutaneous invasive carcinoma: A case report and literature review[J]. Journal of Clinical and Pathological Research, 2018, 38(12): 2743-2748. doi: 10.3978/j.issn.2095-6959.2018.12.039